

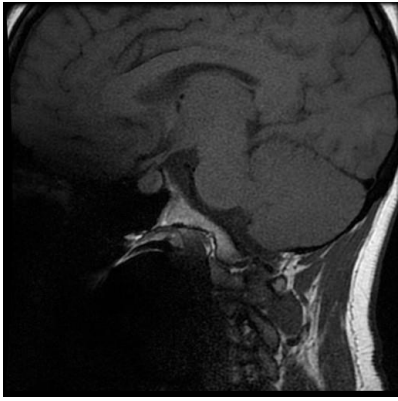Imagen 1: RMN Sagital sin contraste

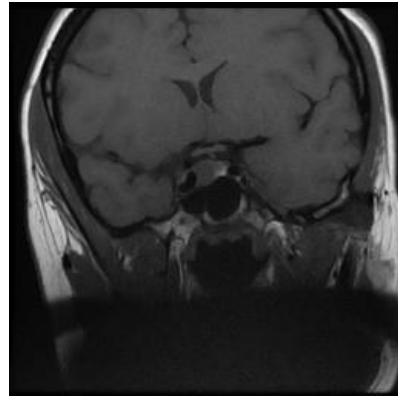


Imagen 2: RMN Coronal sin contraste

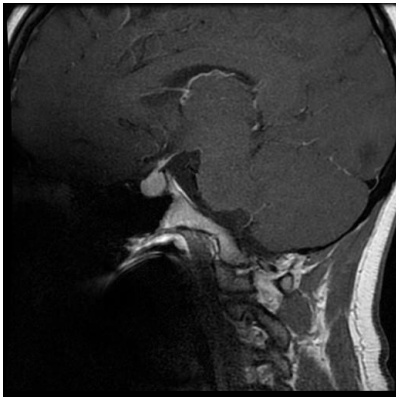


Imagen 3: RMN Sagital con contraste

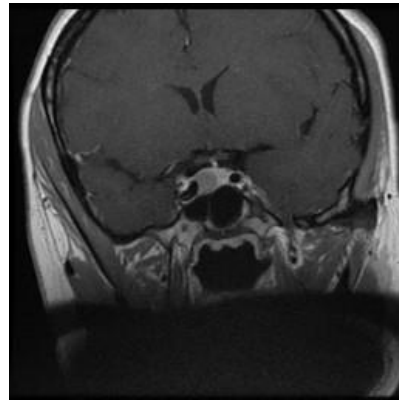


Imagen 4: RMN Coronal con contraste